

Chapter XVI

Percutaneous Biopsy of Parasellar Lesions Through the Foramen Ovale

Mahmoud Messerer^{1,2} and Marc Sindou²

¹Department of Clinical Neurosciences, Department of Neurosurgery, Centre Hospitalier Universitaire Vaudois, Lausanne, Switzerland

²Department of neurosurgery A, Pierre Wertheimer hospital, Hospices civils de Lyon, Lyon, France

Abstract

Parasellar lesions comprise a wide variety of inflammatory and benign or malignant tumorous processes. Each of these lesions requires individual considerations regarding the best management. Percutaneous biopsy through the foramen ovale should be performed in cases of insufficiency of imaging findings to avoid unnecessary open procedures or inappropriate treatment and to guide therapeutic decision. Pathological diagnosis may be sometimes difficult to ascertain with imaging findings. The parasellar region can be reached for biopsy through the foramen ovale percutaneously. After a complete overview of surgical anatomy, the authors describe the used methods. Based on the authors' experience with 50 such procedures, the results are described in terms of diagnostic accuracy and morbidity. Percutaneous biopsy revealed a good diagnostic accuracy with a sensitivity of 83% (CI: 52 – 98) and a specificity of 100% (CI: 79 – 100). No mortality was deplored and morbidity was mostly transient. Indications are lesions located in Meckel's cave, posterior part of the cavernous sinus and upper part of petroclival region.

Introduction

Various types of lesion may appear in the parasellar region, so called "cavernous sinus" and its surroundings. The most frequent encountered tumors are meningiomas but neuromas, chordomas, metastasis and lymphomas are also often seen. Non-tumorous processes such as

inflammatory process can be a differential diagnosis of lesions in the cavernous sinus area [1, 2]). Many lesions in this area have been considered unresectable because of the existence and density of important neurovascular structures [3], and total removal of these various lesions are associated with a relatively high rate of morbidity and mortality [4]. The different surgical open approaches are: the fronto-pteriono-temporal craniotomy to access the Parkinson triangle, the subtemporal approach to reach the Mullan triangle, the pterional approach to reach the roof of the cavernous sinus along the third nerve (Dolenc or Hakuba) or through the carotid ring (Perneczky), the inferomedial wall by transsphenoidal approach (Laws), the contralateral subfrontal approach to access the superomedial wall (Sano), the periauricular infratemporal approach to access the Meckel's cave (Sekhar). Although the microsurgical anatomy of this region has been extensively described in the past [5-11], surgical exposure is still challenging for neurosurgeons. However, several treatment strategies are available. A choice has to be made between radical surgical removal, conservative surgery combined with radiotherapy, medical treatment or simple survey. Furthermore, the choice between surgical or non-surgical treatment is still controversial and the treatment of each lesion requires individual consideration [12-14]. Therefore it is necessary to obtain the exact pathological diagnosis of the lesion in order to establish the best strategy. Current neuroimaging can indirectly provide a diagnosis but lesions in this area are sometimes difficult to characterize radiologically so that a histopathological diagnosis can be necessary with this goal. Percutaneous biopsy through the foramen ovale has been developed. The first description was reported by Stechison and Bernstein [15] in 1989. This technique uses the same approach of the technique for percutaneous treatment of trigeminal neuralgia described by Härtel [16] and Kirschner [17]. This percutaneous biopsy allows performing cytological and/or histopathological examination avoiding unnecessary open craniotomy.

The aim of this chapter is to familiarize readers to the decision-making process for percutaneous biopsy through the foramen ovale. For this goal, authors will recap surgical anatomy and highlight method, indications and results. This chapter is based on the experience of the senior neurosurgeon (M.S.) who operated on 306 central skull base tumors between 1991 and 2010, among which 50 patients benefited from percutaneous biopsy through the foramen ovale.

Surgical Anatomy

An exact knowledge of the anatomical region crossed by the biopsy needle is of paramount importance in order to avoid any complication and to reach correctly the cavernous sinus area. There are three main landmarks, which delineate the triangular bases of the 3D pyramid area with its apex at a cutaneous point 3 cm from the labial commissure:

1. The foramen ovale
2. The cutaneous point 3 cm anterior to the tragus, on the orbito-meatal line along the inferior border of the zygoma.
3. The pupilla

The entry point of the percutaneous needle (Figure 1) is the apex of the pyramidal area i.e. the cutaneous cheek point located 3 cm from the labial commissure.

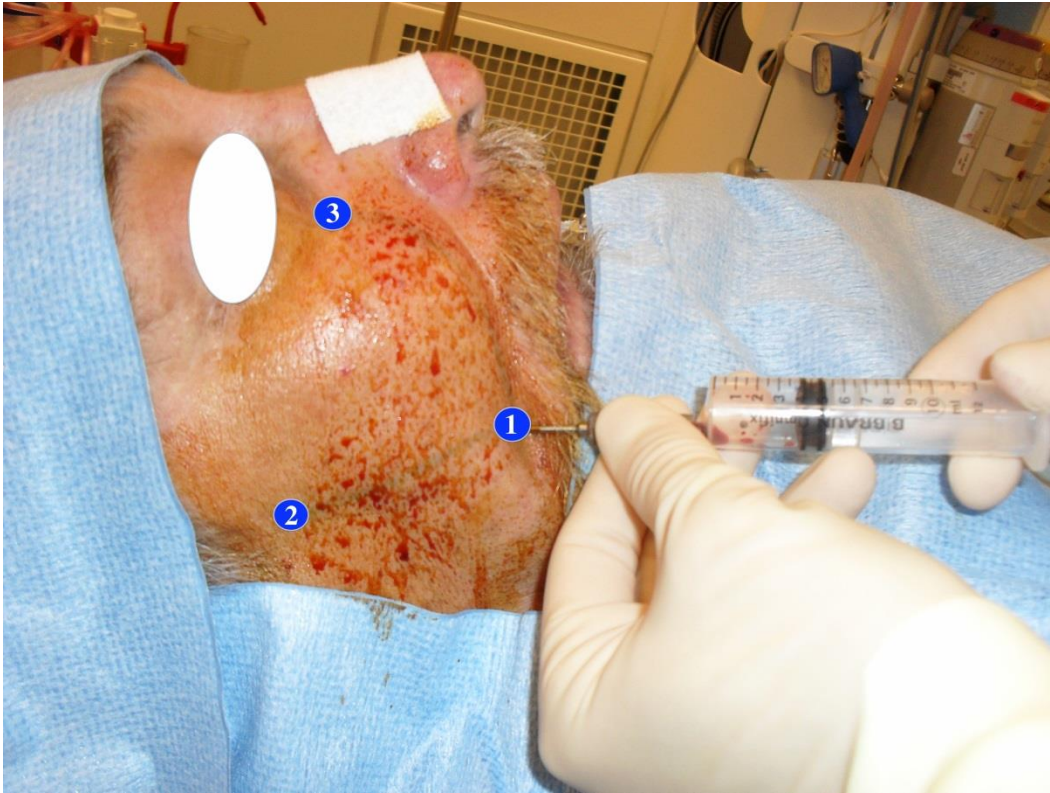

Figure 1. Landmarks for the transjugal-transovale route for percutaneous biopsy. The entry point (1) is located 3 cm from the labial commissure. The trajectory to the foramen ovale is defined by targeting at 35 mm anterior to the tragus (2) in lateral view and the medial border of the pupilla (3) in frontal view. Depth is guided by fluoroscopy.

From this point to the parotid duct, there is the inferior segment that is approximately 13 mm in length. From the parotid duct to the lateral pterygoid muscle, there is the middle segment which lengths approximately 29 mm. It is constituted of fatty tissue and contains the lingual, the chorda tympani, and, the buccal and the inferior alveolar nerves. This segment should be passed very carefully because it is possible to encounter branched of the maxillary artery. From the lateral pterygoid muscle to the foramen ovale, there is the superior segment. This passage should also be made with caution because there is still the possibility to encounter the maxillary artery located posteriorly to the lateral pterygoid muscle. There is also a risk to encounter the pterygoid venous plexuses.

The passage through the foramen ovale leads the needle to the trigeminal cave where it is necessary to be vigilant to the trigeminal system [18]. When reaching the skull base, many structures may be encountered [19]:

- The internal jugular vein: located approximately 27 mm posterolaterally to the right needle trajectory

- The internal carotid artery: located either approximately 25 mm posteriorly to the right needle trajectory into the petrous carotid canal or at the foramen lacerum if cases of deviation of the needle from 10° medially of the correct trajectory
- The inferior and superior orbital fissures, and, the optic nerve, in cases of deviation of the needle from 17° anteriorly of its correct trajectory
- The membranous portion of the auditory tube in cases of deviation of the needle from 9° angle in the anteromedial direction of the correct trajectory

Surgical Procedure

Preoperative Protocol

When preparing a percutaneous biopsy through the foramen ovale, patients should be evaluated preoperatively using Magnetic Resonance Imaging (MRI), Computed Tomography Scanning (CT-scan) and cerebral angiography. MRI evaluation used T1 weighted images with and without enhancement and T2 weighted images in sagittal, coronal and axial planes. This MRI provides information about tumor extent and its relationship with the internal carotid artery. CT-scan with 3D reconstruction provides information regarding bone structures (erosions, calcifications) and the diameter of the foramen ovale. Selective angiographic details tumor's vascularization and allows eliminating an arteriovenous malformation or arterial aneurysm. All these examinations are realized in order to optimize the surgical procedure of the biopsy.

The preoperative evaluation also includes neurootological and ophthalmological examinations.




Figure 2. Biopsy needle (ref Sindou Biopsy Needle N°ACS-976 DIXI microtechniques SAS, 4 chemin de Palente - BP 889, 25025 Besançon, Cedex, France). A: Outer needle introduced first with needle B for puncturing; B: inner solid needle withdrawn when the targeted region is reached; C: inner needle placed into Outer needle to aspirate tissue samples, this needle is connected to a 20 ml syringe allowing strong negative pressure to aspire.

Surgical Steps

Patients are operated using light anesthesia with propofol (Diprivan; Zeneca Pharma, Cergy, France) and local anesthesia with xylocaine at the site of the cheek up to the pterygo-maxillary fossa. Patients are in supine position and the procedure is performed under fluoroscopy. A biopsy needle, a Tuohy's No. 14 needle [20] (Cordis S.A., Sofia Antipolis, France) or a new designed needle (Sindou 2010) (Figure 2) is introduced through the foramen ovale according to the technique used for trigeminal thermorhizotomy [21, 22].

The entry point as described above is located 3 cm lateral to the labial commissure and the right trajectory is to reach the foramen ovale 3 cm anterior to the tragus on a horizontal line corresponding to the inferior border of the zygoma and the pupilla. The location of the needle tip, which reaches to Meckel's cave is confirmed by a lateral view X-Ray (Figure 3).

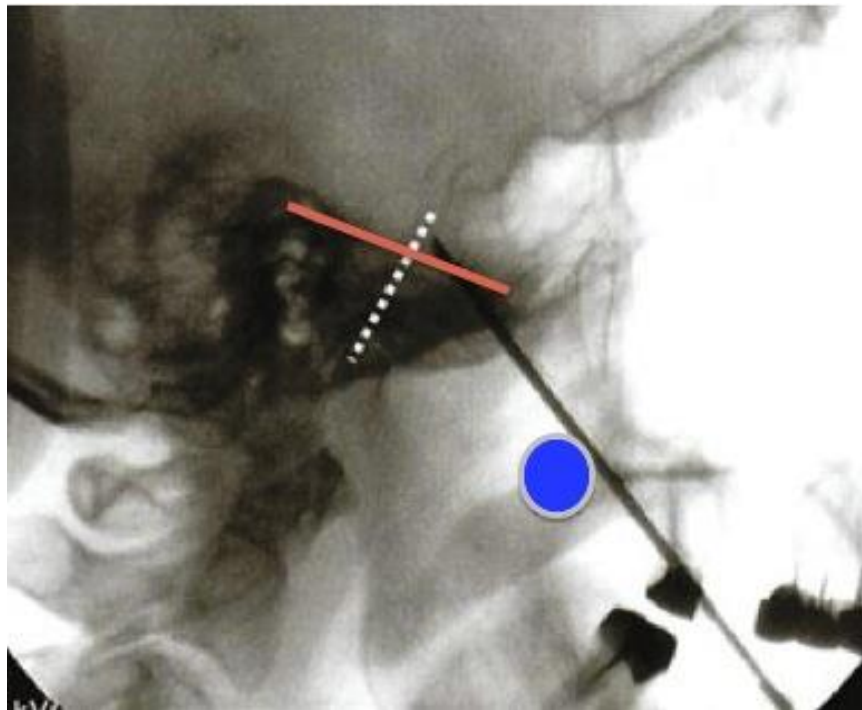


Figure 3. Lateral control X Ray of needle insertion. To be correctly place, the tip of the needle must be approximatively at the intersection between the upper petrous ridge line (continuous line) and the clivus line (dotted line). When entering the pterygo maxillary fossa, note that the projection of the needle passed at the maxillary sinus angle (ovale)

Then, the needle is connected to a 20 ml syringe through which strong negative pressure is applied, and at least two specimens of soft consistency without any trouble are obtained.

In all the cases, the cytological specimens are studied using the May-Grunwald staining technique, either directly or after centrifugation. Preliminary staining and microscopic examination of each specimen are performed extemporaneously at the department of histology. When the samples are big enough, additional conventional histological techniques and study of the immunological markers are added.

Indications for Percutaneous Biospy – Management

A recent published article [23] on a series of 50 patients by Messerer et al. the senior author (MS) discussed the percutaneous biopsy of cavernous sinus lesions, i.e. cavernous sinus, Meckel's cave and petroclival apex region, through the foramen ovale.

There are a great variety of symptoms that can reveal a mass lesion of the cavernous sinus area, including benign or malign tumors. Some symptoms have been described in the literature to be more frequent in certain lesions. For instance, patients with malignant lesions of the Meckel's cave may be more likely to suffer paresthesiae and trigeminal motor deficits than those with meningiomas [24]. However, it is really important to notice that any symptom or association of symptoms cannot be considered as a specific sign of a disease. Every symptom may reveal every disease.

By comparison with this great variety of symptoms, there are also a great variety of lesions that can match with many types of symptoms and each lesion may require its own treatment strategy. The cavernous sinus and its surroundings can be invading by intrinsic tumors such as trigeminal neuromas, meningiomas, congenital tumors (epidermoid cysts, lipomas and dermoids), or, by secondary tumors which consist in retrograde perineural extension along the trigeminal nerve or in subarachnoid dissemination and metastasis from extracranial malignancy [25]. The incidence of cancer first presenting as one or more metastatic intracranial lesions is between 5% and 12% [26]. Furthermore, it is difficult to distinguish metastatic tumors from benign tumors solely based on clinical or radiographic characteristics, especially in those patients without an identified primary malignancy at the time of presentation. In a historic series of 137 cavernous sinus, there were 37% of malignant lesions described by Sekhar et al. [6] in 1991.

In the beginning of the nineties, the treatment of cavernous sinus lesions was practically exclusively surgical with the will of neurosurgeons to obtain gross total removals. This surgical treatment was associated with a relatively high rate of morbidity [4, 9, 27]. However from the end of this decade, a bend was marked with the advent of oncological treatment such as radiosurgery and, other approaches to treatment were advocated with the aim of achieving an optimal life quality [28, 29]. Coppa et al. [30] reported that surgical resection of skull base malignancies may no longer be the "gold standard" or optimal first line treatment thanks to the advent of radiosurgery. For instance, for a meningioma that is not resectable, many studies demonstrated a high degree of local tumor control after radiosurgery [28]. Pollock et al. [31], in a series of 198 meningiomas, demonstrated that radiosurgery provided superior tumor control for patients with either a Grade 2 or Grade 3 – 4 resection. Therefore when mass lesions are revealed during diagnostic evaluation, tissue diagnoses should be obtained because it is absolutely necessary to establish an exact pathological diagnosis in order to provide the best management and to avoid unnecessary surgical procedures and its associated morbidity.

Our series published in the literature [23] represents the largest series of percutaneous biopsy through the foramen ovale for the diagnosis of cavernous sinus area lesions. Since its first description in 1989 by Stechison et al. [15], studies have been involved but they only reported few cases [32-34] preventing the analysis of their diagnostic accuracy. Only one report included more than five patients [20]. Our series allowed us to evaluate the diagnostic accuracy of the percutaneous biopsy in comparison with histopathological examination which came from a second surgery. The sensitivity to distinguish benign and malign tumors was

83% (CI: 52 – 98) and the specificity was 100% (CI: 79 – 100). In addition, the kappa coefficient showed a good correlation in terms of histopathological diagnosis between biopsy results and histopathological results from another surgery.

Although this diagnostic test is not perfect, it can be used as a useful add-on test in order to identify the pathological diagnosis of cavernous sinus area lesions. Figures 4, 5, 6 and 7 show sample examples of imaging, biopsy and/or histopathological (from open surgery) findings for some patients.

In addition, percutaneous biopsy via the foramen ovale for cavernous sinus area lesions and percutaneous trigeminal rhizotomies has been reported previously and is considered to be a minimal invasive procedure without major complications [20, 33, 35]. In our published study [23], we encountered two complications: a face cellulitis and a cheek hematoma likely due to a vascular injury of the maxillary artery that is located on the very trajectory of the needle [36].

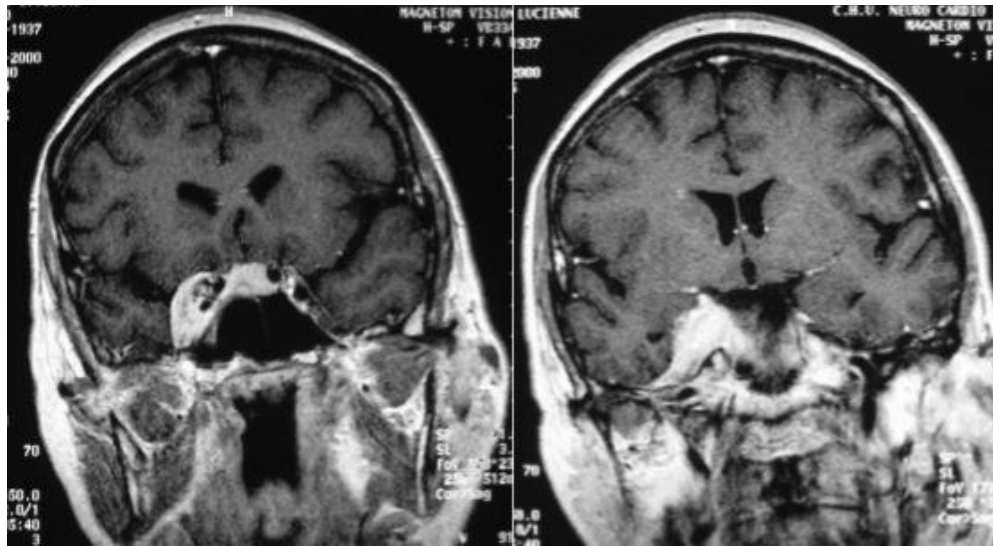


Figure 4. Coronal T1-weighted images with gadolinium enhancement showing a lesion into the right cavernous sinus with a floor middle fossa extension. Percutaneous biopsy stated for a meningioma, which was confirmed at open surgery.

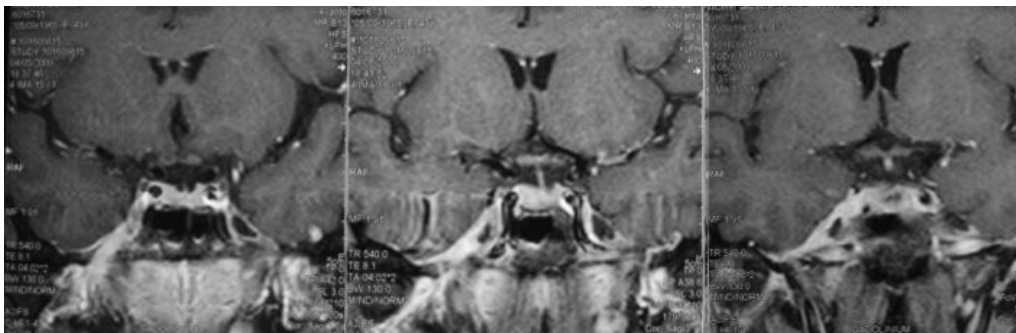

Figure 5. Coronal T1-weighted images with gadolinium enhancement showing a lesion into the right cavernous sinus extending to the tentorial incisura, suggesting a meningioma. Percutaneous biopsy stated for an inflammatory pseudotumor. Lesion regressed after corticosteroid treatment.

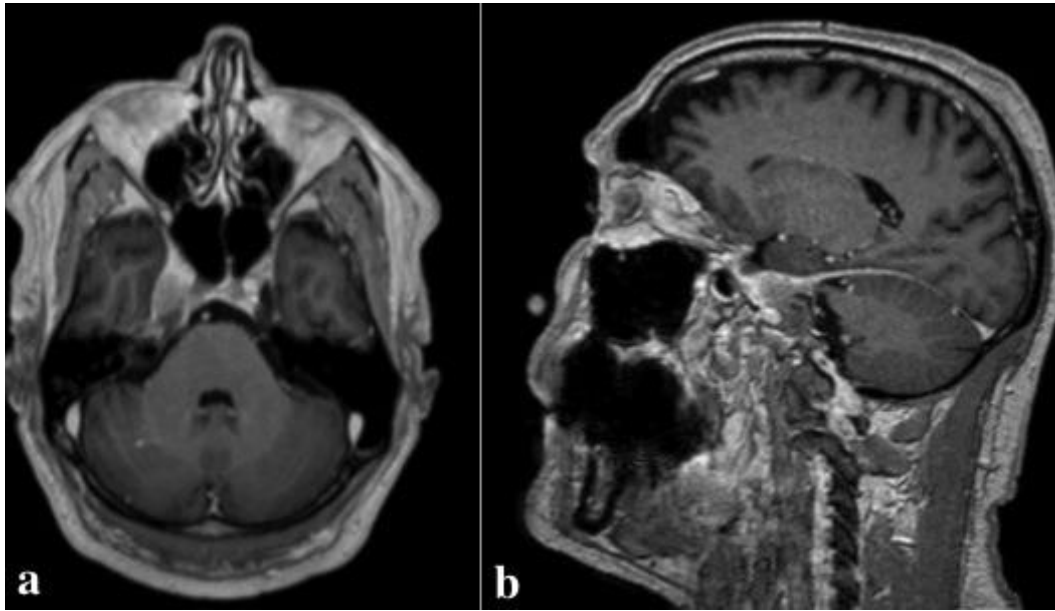


Figure 6. a: Axial T1-weighted MR images, and, b: sagittal T1-weighted MR image, with gadolinium enhancement showing a lesion into the right cavernous sinus extending to the pterygomaxillary fossa. Percutaneous biopsy stated for an adenocarcinoma and the patient was treated with chemotherapy.

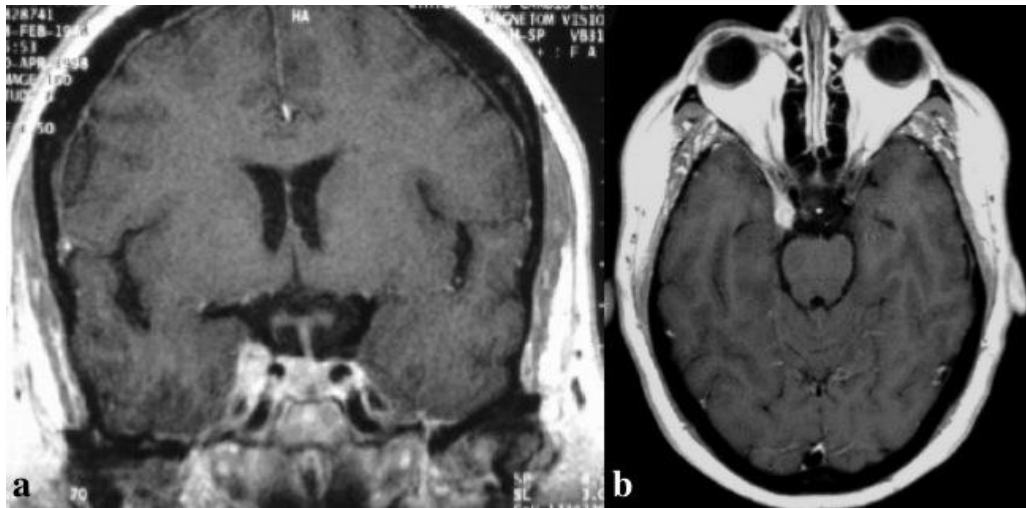


Figure 7. a: Coronal T1-weighted MR image and, b: axial T1-weighted image, with gadolinium enhancement showing a lesion into the right cavernous sinus. This patient was initially referred for diplopia due to a right oculomotor nerve palsy. Percutaneous biopsy stated for an inflammatory pseudotumor. Lesion totally regressed after corticosteroid treatment.

The major inconvenience of the percutaneous biopsy is the difficulty in obtaining a sufficient fragment of pathological processes in order to allow a cytohistopathological examination. Though, it is necessary to have a close cooperation between the referring neurosurgeon and the cytopathologist. Another problem is the relatively high frequency of presence of meningeal cells in fragments of lesions, which are not meningiomas. This is

certainly due to the effraction of the meninges during the biopsy. So it can lead to a wrong diagnosis when no other types of cells are present in the fragment due to a wrong biopsy.

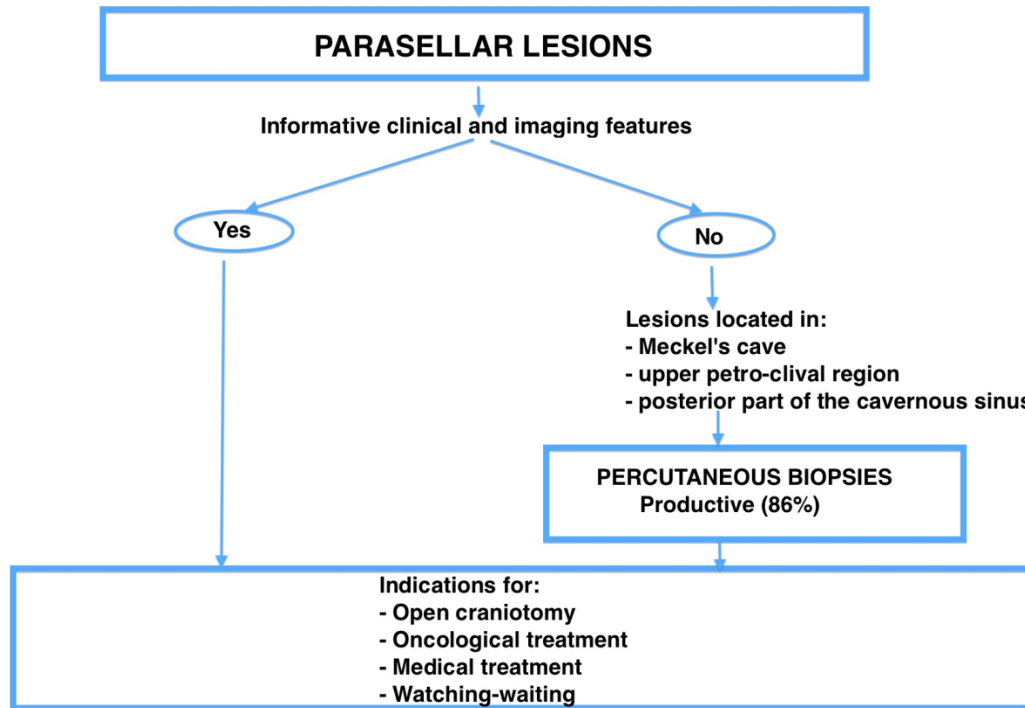


Figure 8. Decision making process for parasellar lesions.

Conclusion

In the argument above, authors recommend performing percutaneous biopsies of the cavernous sinus area lesions through the foramen ovale in all cases of lesions located in the Meckel’s cave; posterior part of the cavernous sinus and the upper part of the petroclival region. Especially when neuro-imaging does not provide sufficient information on the histopathological nature of the pathological process. In the function of biopsy results, individual consideration with regards management could be made (Figure 8).

Percutaneous biopsy of lesions through the foramen ovale is an accurate and useful method to orientate the management of parasellar lesions by avoiding unnecessary open craniotomy and its rate of morbi-mortality. The authors recommend performing a percutaneous biopsy in cases of an insufficiently established pathological diagnosis of clinic-radiological findings.

References

- [1] Ahn JY, Kwon SO, Shin MS, Joo JY, Kim TS. Chronic granulomatous neuritis in idiopathic trigeminal sensory neuropathy. Report of two cases. *Journal of neurosurgery*. 2002;96(3):585-8. Epub 2002/03/09.
- [2] Gottfried ON, Chin S, Davidson HC, Couldwell WT. Trigeminal amyloidoma: case report and review of the literature. *Skull base : official journal of North American Skull Base Society* [et al]. 2007;17(5):317-24. Epub 2008/03/12.
- [3] Duma CM, Lunsford LD, Kondziolka D, Harsh GRt, Flickinger JC. Stereotactic radiosurgery of cavernous sinus meningiomas as an addition or alternative to microsurgery. *Neurosurgery*. 1993;32(5):699-704; discussion -5. Epub 1993/05/01.
- [4] Al-Mefty O, Smith RR. Surgery of tumors invading the cavernous sinus. *Surg Neurol*. 1988;30(5):370-81. Epub 1988/11/01.
- [5] Sindou M, Alaywan M. [Orbital and/or zygomatic removal in an approach to lesions near the cranial base. Surgical technic, anatomic study and analysis of a series of 24 cases]. *Neurochirurgie*. 1990;36(4):225-33. Epub 1990/01/01. La depose orbitaire et/ou zygomatique dans l'abord des lesions proches de la base du crane. Technique chirurgicale, etude anatomique et analyse d'une serie de 24 cas.
- [6] Sekhar LN, Pomeranz S, Sen CN. Management of tumours involving the cavernous sinus. *Acta Neurochir Suppl* (Wien). 1991;53:101-12. Epub 1991/01/01.
- [7] Inoue T, Rhoton AL, Jr., Theele D, Barry ME. Surgical approaches to the cavernous sinus: a microsurgical study. *Neurosurgery*. 1990;26(6):903-32. Epub 1990/06/01.
- [8] Kawase T, van Loveren H, Keller JT, Tew JM. Meningeal architecture of the cavernous sinus: clinical and surgical implications. *Neurosurgery*. 1996;39(3):527-34; discussion 34-6. Epub 1996/09/01.
- [9] Hakuba A, Tanaka K, Suzuki T, Nishimura S. A combined orbitozygomatic infratemporal epidural and subdural approach for lesions involving the entire cavernous sinus. *Journal of neurosurgery*. 1989;71(5 Pt 1):699-704. Epub 1989/11/01.
- [10] Emery E, Alaywan M, Sindou M. [Respective indications of orbital and/or zygomatic arch removal combined with fronto-pteriono-temporal approaches. 58 cases]. *Neurochirurgie*. 1994;40(6):337-47. Epub 1994/01/01. Indications respectives des depotes orbitaires et/ou zygomatiques en association aux abords fronto-pteriono-temporaux. 58 cas.
- [11] Sindou M, Emery E, Acevedo G, Ben-David U. Respective indications for orbital rim, zygomatic arch and orbito-zygomatic osteotomies in the surgical approach to central skull base lesions. Critical, retrospective review in 146 cases. *Acta Neurochir* (Wien). 2001;143(10):967-75. Epub 2001/10/31.
- [12] Cusimano MD, Sekhar LN, Sen CN, Pomonis S, Wright DC, Biglan AW, et al. The results of surgery for benign tumors of the cavernous sinus. *Neurosurgery*. 1995;37(1):1-9; discussion -10. Epub 1995/07/01.
- [13] Anand VK, House JR, 3rd, al-Mefty O. Management of benign neoplasms invading the cavernous sinus. *Laryngoscope*. 1991;101(5):557-64. Epub 1991/05/01.
- [14] Eisenberg MB, Al-Mefty O, DeMonte F, Burson GT. Benign nonmeningeal tumors of the cavernous sinus. *Neurosurgery*. 1999;44(5):949-54; discussion 54-5. Epub 1999/05/08.

-
- [15] Stechison MT, Bernstein M. Percutaneous transfacial needle biopsy of a middle cranial fossa mass: case report and technical note. *Neurosurgery*. 1989;25(6):996-9. Epub 1989/12/01.
- [16] Härtel F. Die leitungsanästhesie und injektionbehandlung des ganglion gasseri und der trigeminusstämme. *Arch Klin Chir*. 1912;100:627-38.
- [17] Kirschner M. Blektrocoagulation des ganglion gasseri. *Zentralbl Chir*. 1932;47:2841-3.
- [18] Alvernia J, Wydh E, Simon E, Sindou M, Mertens P. [Microsurgical anatomy of the transoval percutaneous route to the trigeminal cave and the trigeminal ganglion]. *Neurochirurgie*. 2009;55(2):87-91. Epub 2009/03/31. Anatomie microchirurgicale de la voie percutanee transovale vers la cavite trigeminale et le ganglion trigeminal (voie de Hartel).
- [19] Alvernia JE, Sindou MP, Dang ND, Maley JH, Mertens P. Percutaneous approach to the foramen ovale: an anatomical study of the extracranial trajectory with the incorrect trajectories to be avoided. *Acta Neurochir (Wien)*. 2010;152(6):1043-53. Epub 2010/02/09.
- [20] Sindou M, Chavez JM, Saint Pierre G, Jovet A. Percutaneous biopsy of cavernous sinus tumors through the foramen ovale. *Neurosurgery*. 1997;40(1):106-10; discussion 10-1. Epub 1997/01/01.
- [21] Sindou M, Fobe JL, Berthier E, Vial C. Facial motor responses evoked by direct electrical stimulation of the trigeminal root. Localizing value for radiofrequency thermorhizotomy. *Acta Neurochir (Wien)*. 1994;128(1-4):57-67. Epub 1994/01/01.
- [22] Sweet WH, Wepsic JG. Controlled thermocoagulation of trigeminal ganglion and rootlets for differential destruction of pain fibers. 1. Trigeminal neuralgia. *J Neurosurg*. 1974;40(2):143-56. Epub 1974/02/01.
- [23] Messerer M, Dubourg J, Saint-Pierre G, Jouanneau E, Sindou M. Percutaneous biopsy of lesions in the cavernous sinus region through the foramen ovale: diagnostic accuracy and limits in 50 patients. *Journal of neurosurgery*. 2012;116(2):390-8. Epub 2011/11/22.
- [24] Soni CR, Kumar G, Sahota P, Miller DC, Litofsky NS. Metastases to Meckel's cave: Report of two cases and comparative analysis of malignant tumors with meningioma and schwannoma of Meckel's cave. *Clin Neurol Neurosurg*. Epub 2010/08/24.
- [25] Beck DW, Menezes AH. Lesions in Meckel's cave: variable presentation and pathology. *J Neurosurg*. 1987;67(5):684-9. Epub 1987/11/01.
- [26] Sawaya R. *Intracranial metastases*. Current management strategies: Blackwell Futura; 2004.
- [27] DeMonte F, Smith HK, al-Mefty O. Outcome of aggressive removal of cavernous sinus meningiomas. *J Neurosurg*. 1994;81(2):245-51. Epub 1994/08/01.
- [28] Milker-Zabel S, Zabel-du Bois A, Huber P, Schlegel W, Debus J. Fractionated stereotactic radiation therapy in the management of benign cavernous sinus meningiomas : long-term experience and review of the literature. *Strahlenther Onkol*. 2006;182(11):635-40. Epub 2006/10/31.
- [29] Long DM. The treatment of meningiomas in the region of the cavernous sinus. *Childs Nerv Syst*. 2001;17(3):168-72. Epub 2001/04/18.
- [30] Coppa ND, Raper DM, Zhang Y, Collins BT, Harter KW, Gagnon GJ, et al. Treatment of malignant tumors of the skull base with multi-session radiosurgery. *J Hematol Oncol*. 2009;2:16. Epub 2009/04/04.

-
- [31] Pollock BE, Stafford SL, Utter A, Giannini C, Schreiner SA. Stereotactic radiosurgery provides equivalent tumor control to Simpson Grade 1 resection for patients with small-to medium-size meningiomas. *Int J Radiat Oncol Biol Phys*. 2003;55(4):1000-5. Epub 2003/02/28.
- [32] Yi W, Ohman K, Brannstrom T, Bergenheim AT. Percutaneous biopsy of cavernous sinus tumour via the foramen ovale. *Acta Neurochir (Wien)*. 2009;151(4):401-7; discussion 7. Epub 2009/03/07.
- [33] Dresel SH, Mackey JK, Lufkin RB, Jabour BA, Desalles AA, Layfield LJ, et al. Meckel cave lesions: percutaneous fine-needle-aspiration biopsy cytology. *Radiology*. 1991;179(2):579-82. Epub 1991/05/01.
- [34] Berk C, Honey CR. Percutaneous biopsy through the foramen ovale: a case report. *Stereotact Funct Neurosurg*. 2002;78(1):49-52. Epub 2002/10/17.
- [35] Kanpolat Y, Savas A, Bekar A, Berk C. Percutaneous controlled radiofrequency trigeminal rhizotomy for the treatment of idiopathic trigeminal neuralgia: 25-year experience with 1,600 patients. *Neurosurgery*. 2001;48(3):524-32; discussion 32-4. Epub 2001/03/29.
- [36] Alvernia JE, Sindou MP, Dang ND, Maley JH, Mertens P. Percutaneous approach to the foramen ovale: an anatomical study of the extracranial trajectory with the incorrect trajectories to be avoided. *Acta Neurochir (Wien)*. 152(6):1043-53. Epub 2010/02/09.